

Indications et Techniques

Les séquelles traumatiques

Ph. Valenti, J. Kany, D. Katz

Paris Shoulder Unit

Clinique Bizet (Paris, France)

Disclosures

Arthroplasty

Consultant : FH orthopaedics
receive royalties

Arthroscopy

Consultant : Zimmer Biomet
Arthrex

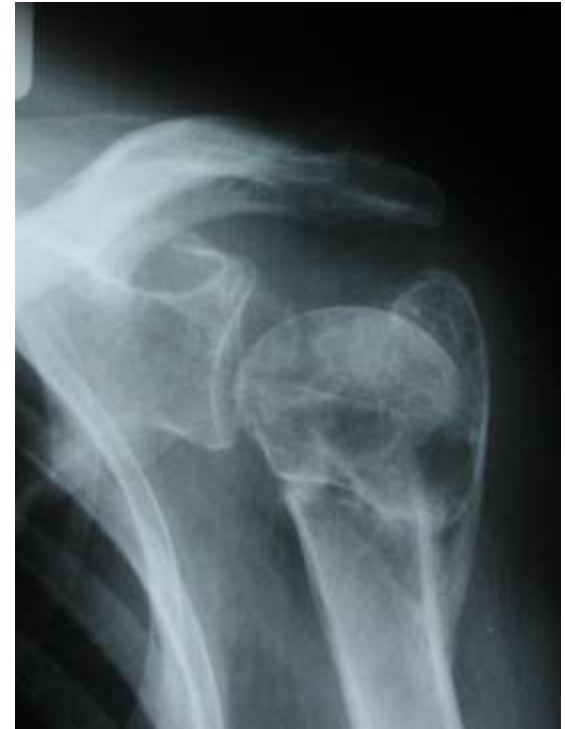Sequeleas of proximal humeral fracture

Complex challenge
for any surgeon

Clinical evaluation

Radiographic analysis

Treatment options



Best treatment
Good treatment!!! in emergency
PREVENTION

Clinical evaluation

History of the fracture

Age, sexe, workercompensation

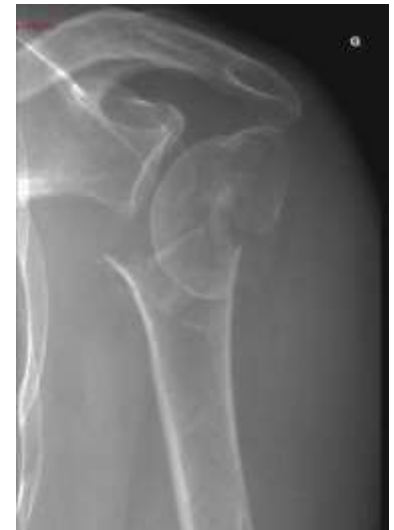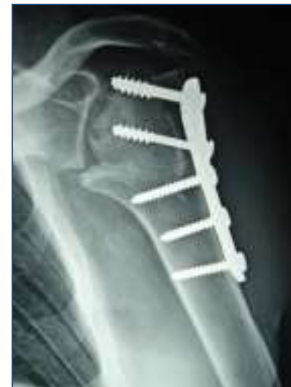Initial fracture (2/3/4 fragments / displacement/
Dislocation)

Initial treatment

closed / open / ORIF/ Prothesis

Delay since Initial treatment

Infection



Clinical evaluation

Pain VAS (0/10)

Trophicity Deltoid Cuff (SSC, SS, IS)

Range of motion

Active (Lack AE ER IR)

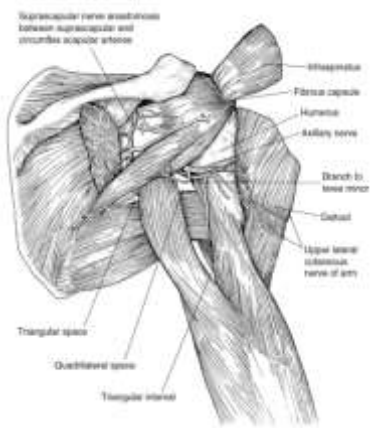
Passive

SA impingement

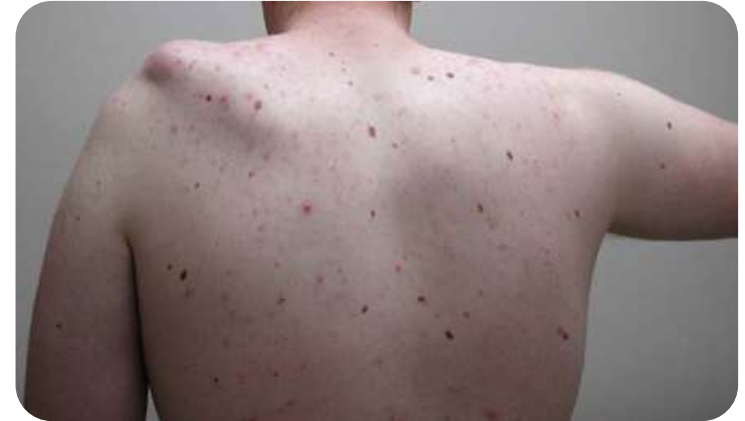STIFF
shoulder

Constant / ASES / SST / SSV
scores

Neurological evaluation



Deltoid / SS IS atrophy
Pseudo tinel

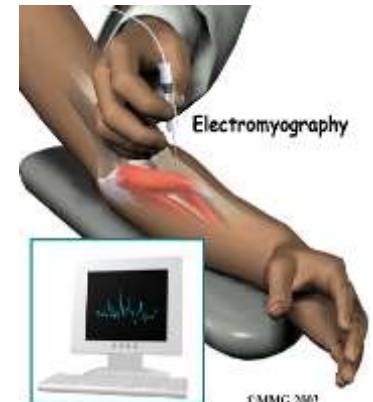


EMG and nerve conduction study

Axillary nerve

Suprascapular nerve

(violent trauma / displaced Fract)

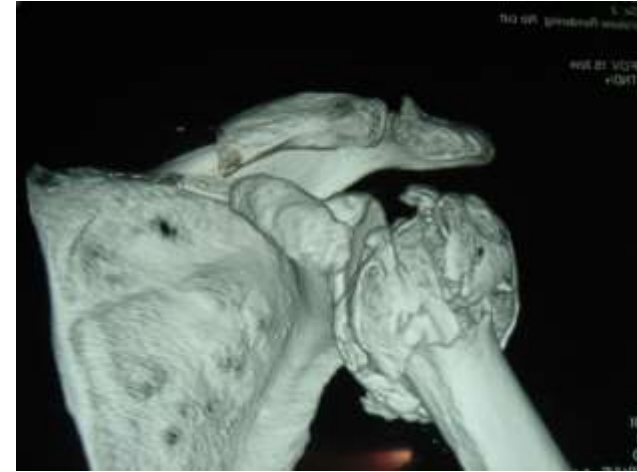

Radiographic evaluation

Standards X rays

AP / Outlet / axillary views

CT Scan +++ MRI



- **Great tuberosity +++(cuff)**
- Humeral Head (necrosis)
- Surgical neck Less tuberosity
- Soft Tissue(Cuff / deltoid/ LHB)
- Cartilage

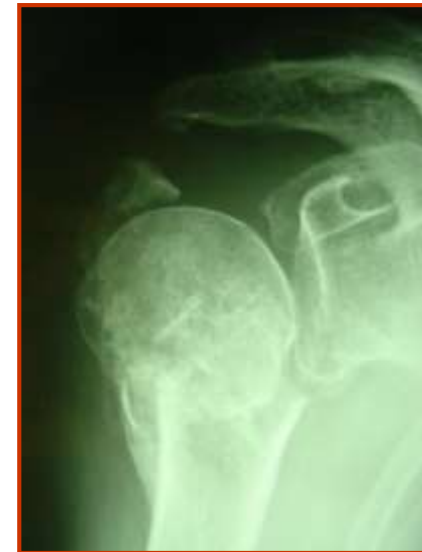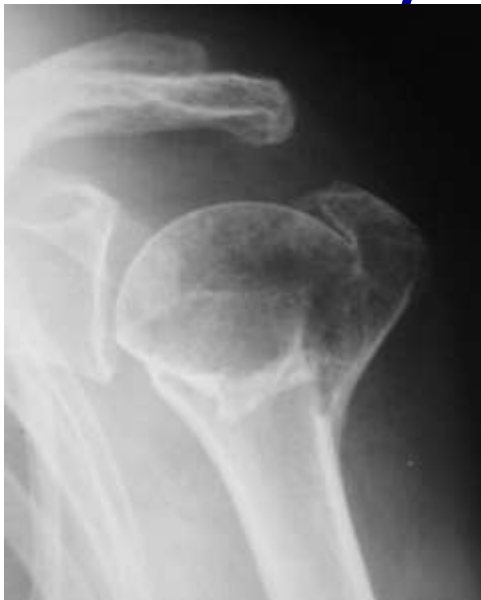Standards X Rays

How to analyse Great tuberosity ?

Union : continuity with the diaphysis

Non union : not healing > 6months

Malunion : >5-10mm of displacement
cuff dysfunction



Standards X Rays

How to analyse Humeral head ?

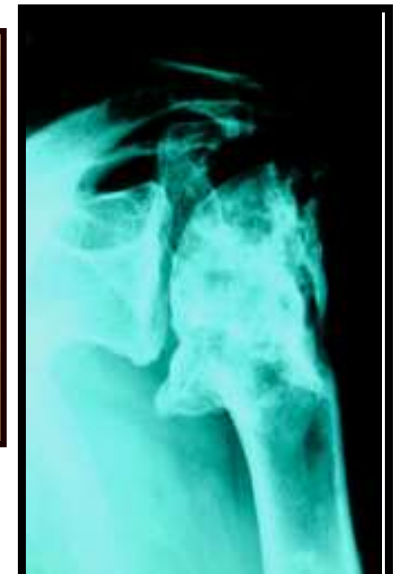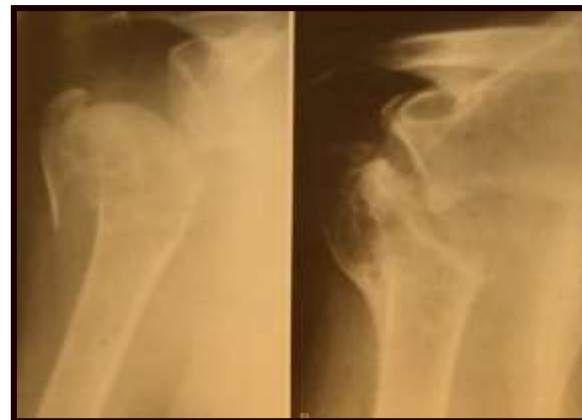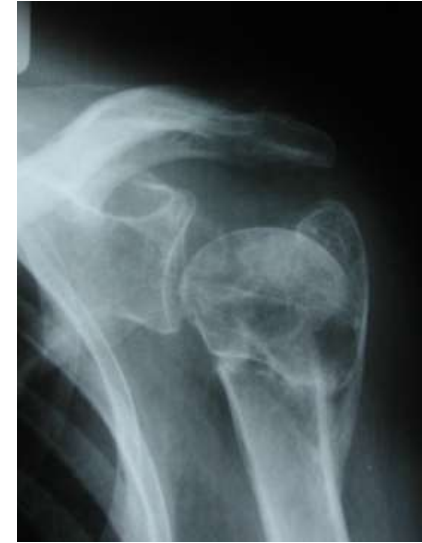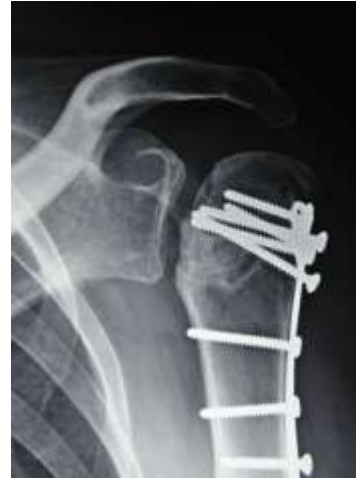Necrosis

Impaction valgus

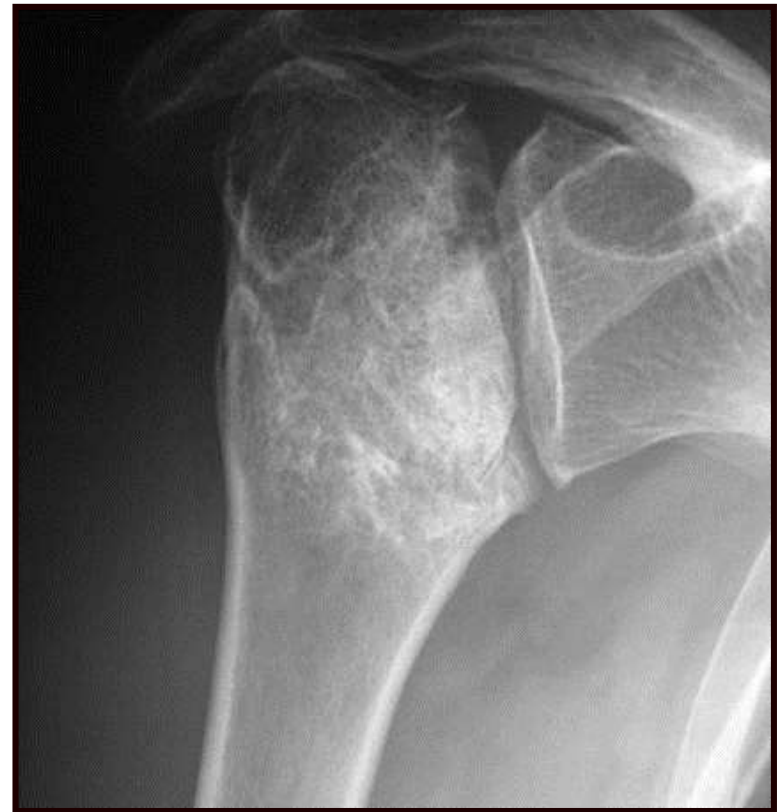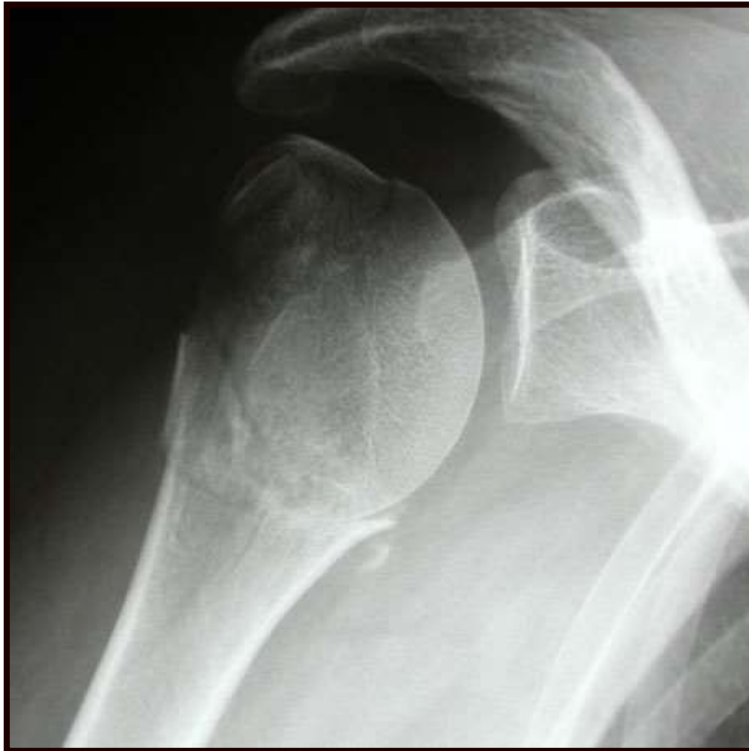Impaction varus

Posterior dislocation

Anterior dislocation



AVNecrosis after Functionnal treatment !!!!



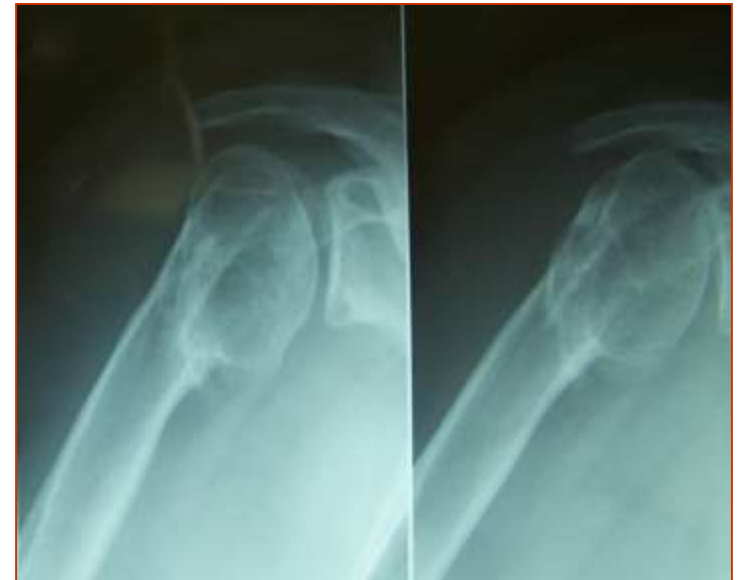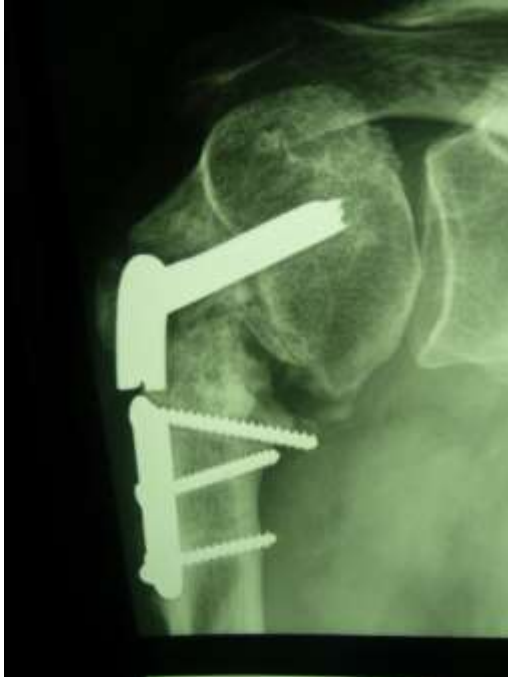Standards X Rays

How to analyse surgical Neck ?

Union

Non union :not healing >6months

Malunion: Varus / valgus



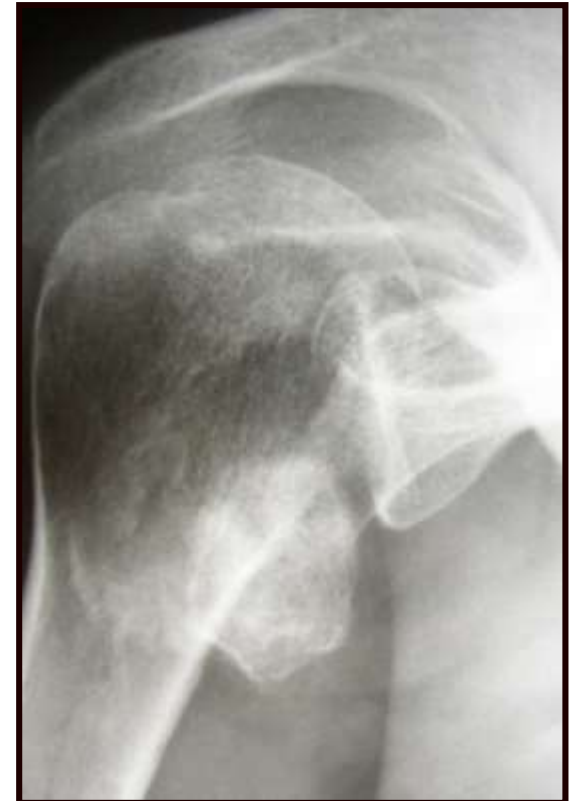Standards X Rays

How to analyse less tuberosity ?

Union

Non union :not healing >
6months

Malunion: medial
displacement with medial
impingement less strength
IR



CTScan versus MRI

Better analysis bone deformity

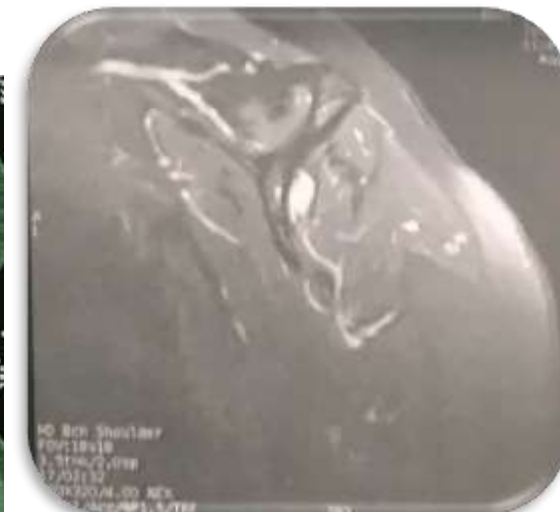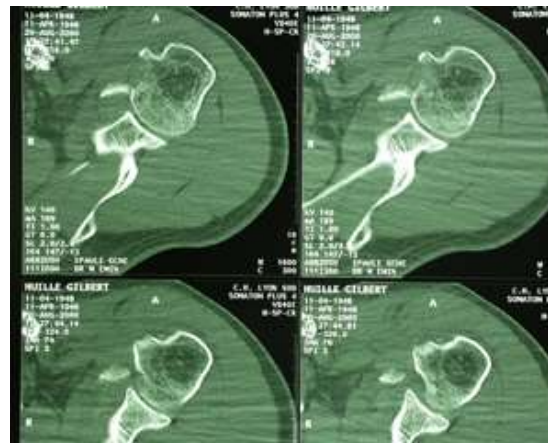
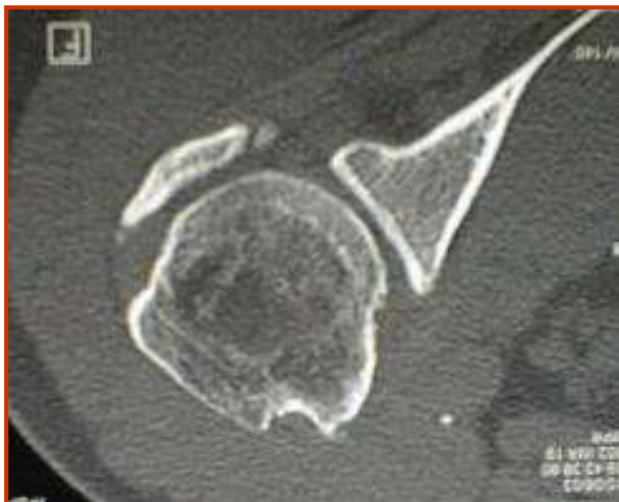
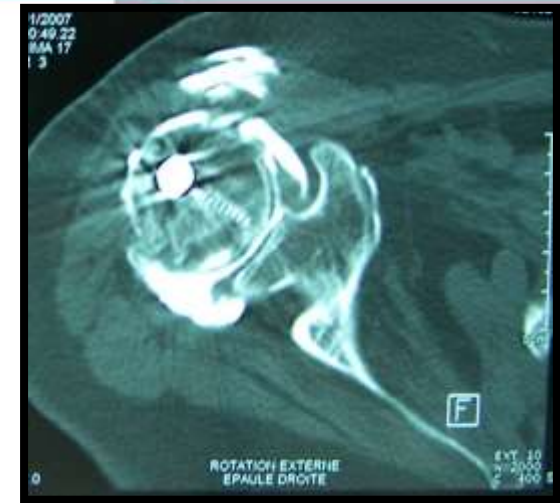Quality of the bone

Osteoporosis / density H Head / necrosis

Cartilage wear (glenoid)

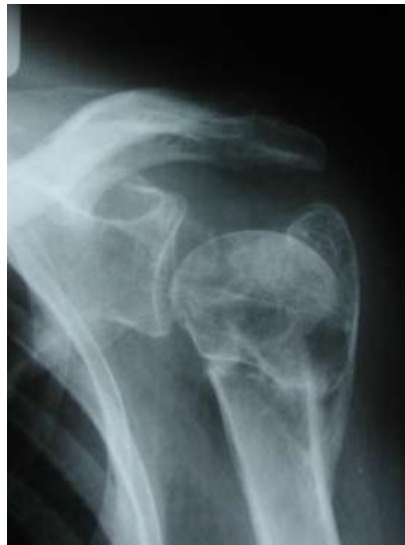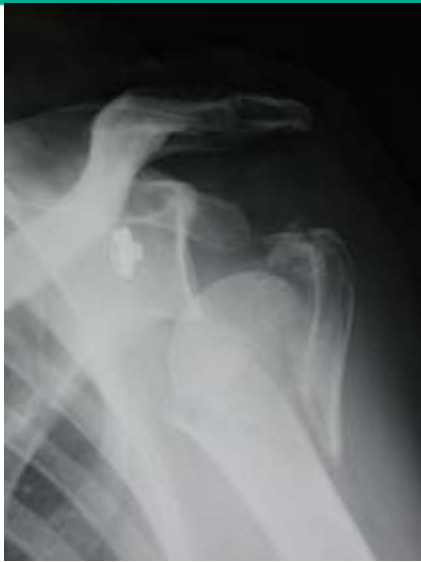Muscular Trophicity and degree Fatty degeneration

Long head biceps



Therapeutic options

Conservative
Surgical



Malunion sometimes
well tolerated
NO sophisticated operation
conservative treatment



Stiff shoulder

- *No bone deformity*

Physiotherapy (injections) +++

Arthrolysis @

Removal hardware

- *Glenoid cartilage erosion*

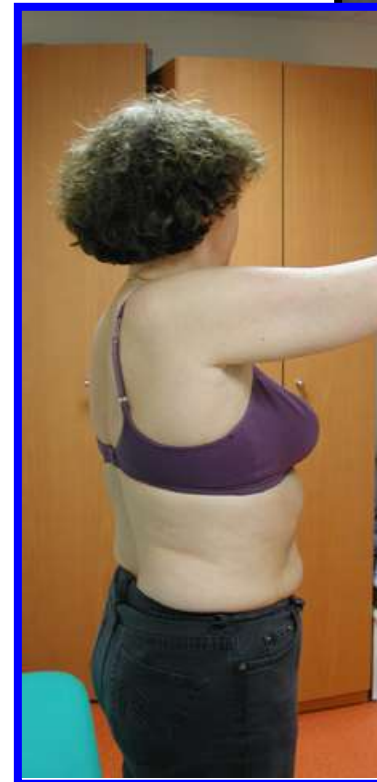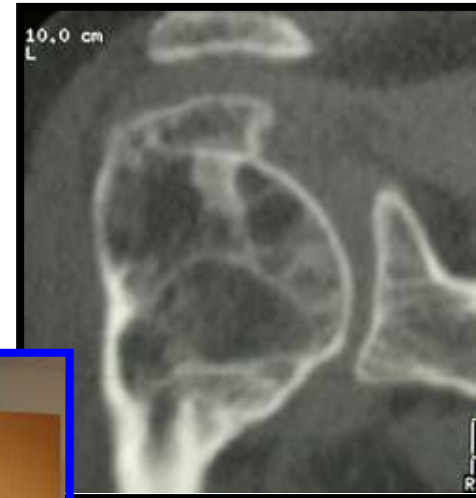Arthrolysis@

Anatomic TSA

Stiff shoulder

bone deformity fonctionnal cuff

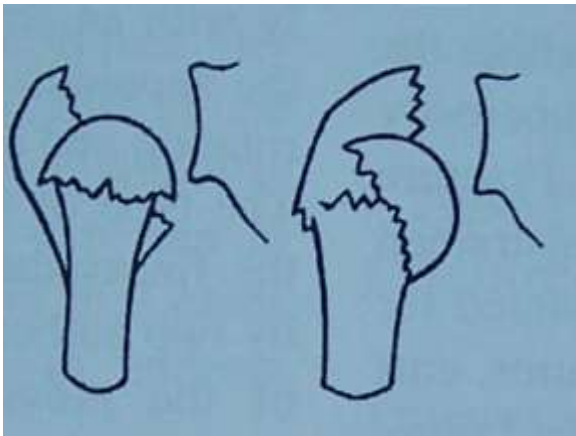
- *GT malunion*
Tuberopecty @
Acromioplasty @
Osteotomy tuberositie
- *Humeral head necrosis*
Hemiarthroplasty
Anatomic TSA(glenoid cartilage wear)
- *LT malunion*
Osteotomy



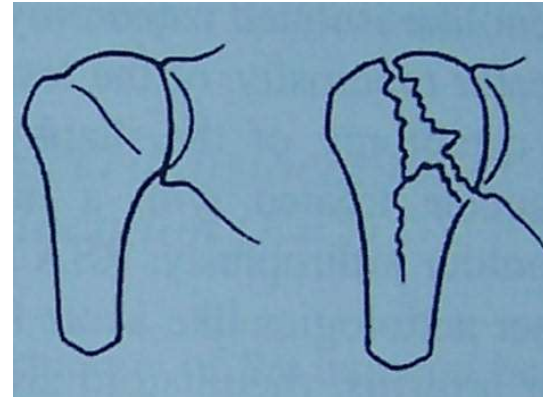
HH fracture sequelae classification

Walch, Boileau, JSES, 2001

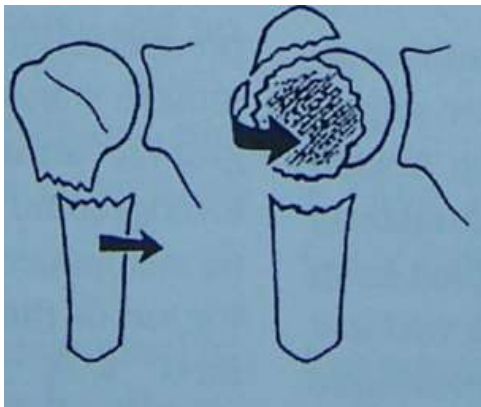
Type I: Cephalic collaps or Necrosis



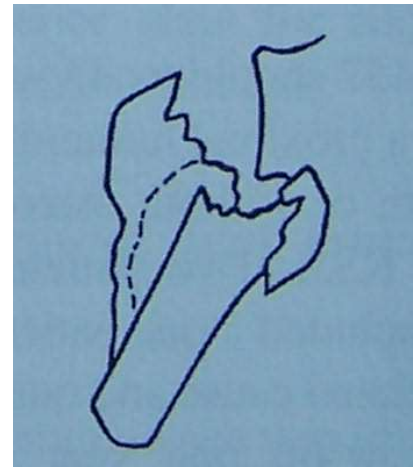Type II: Locked dislocation or fracture dislocation



Type III: Surgical neck non union



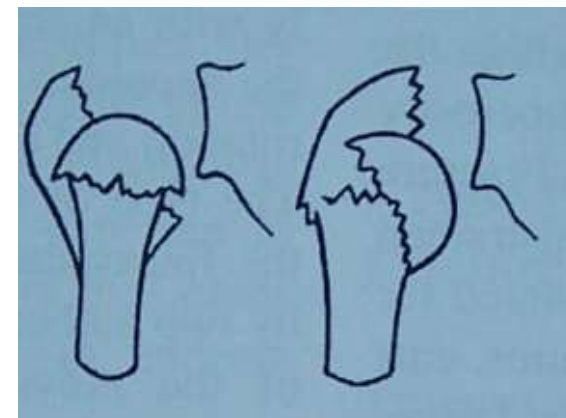
Type IV: Severe tuberosity malunion



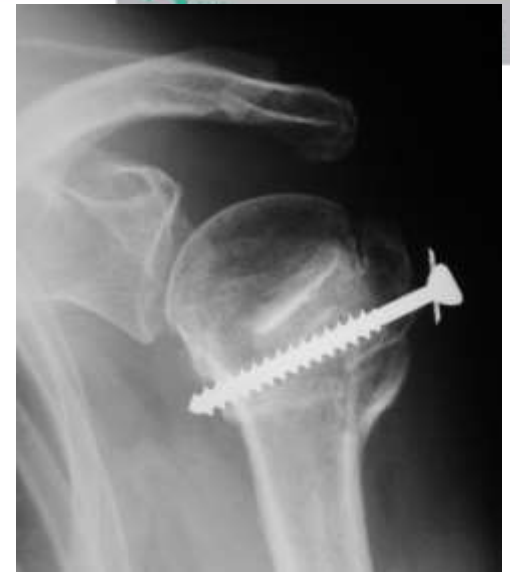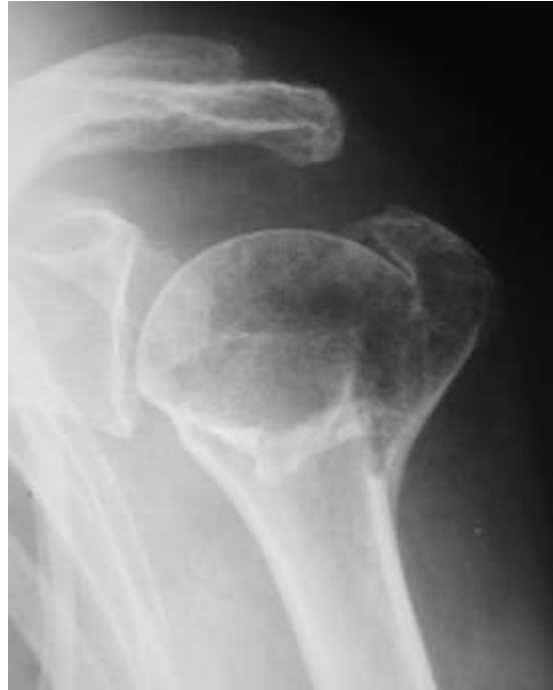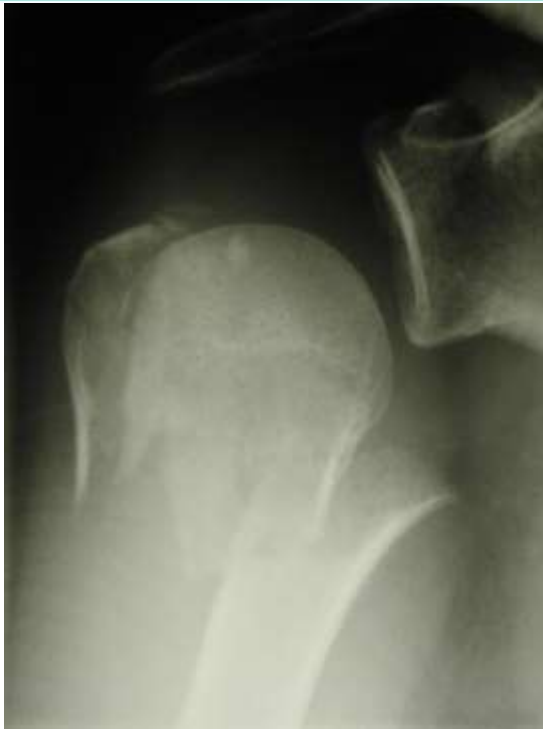Type 1: impacted valgus/varus fracture cephalic collapse / necrosis

Functionnal cuff +++

- Osteotomy GT +H Head
- Hemiarthroplasty
- Anatomic TSA (glenoid wear)

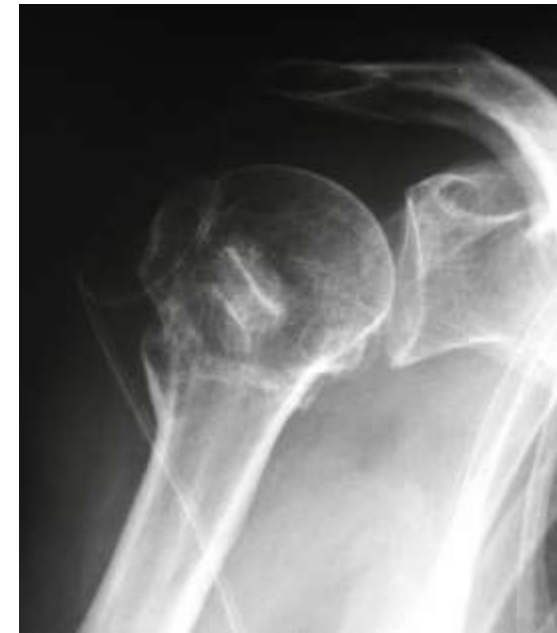

No osteotomy of the tuberosity
if you arthroplasty ++

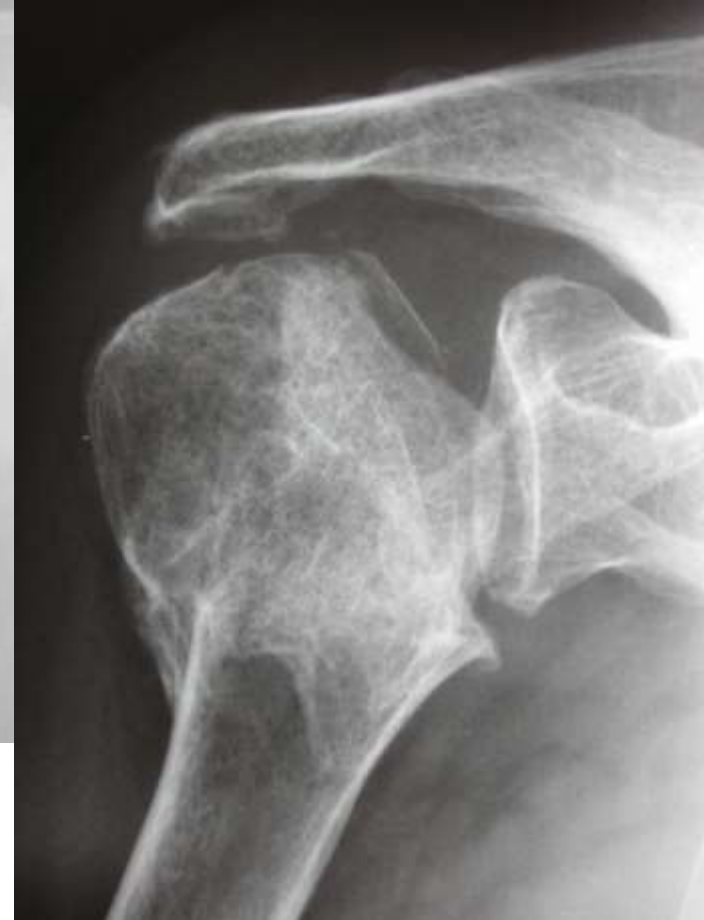
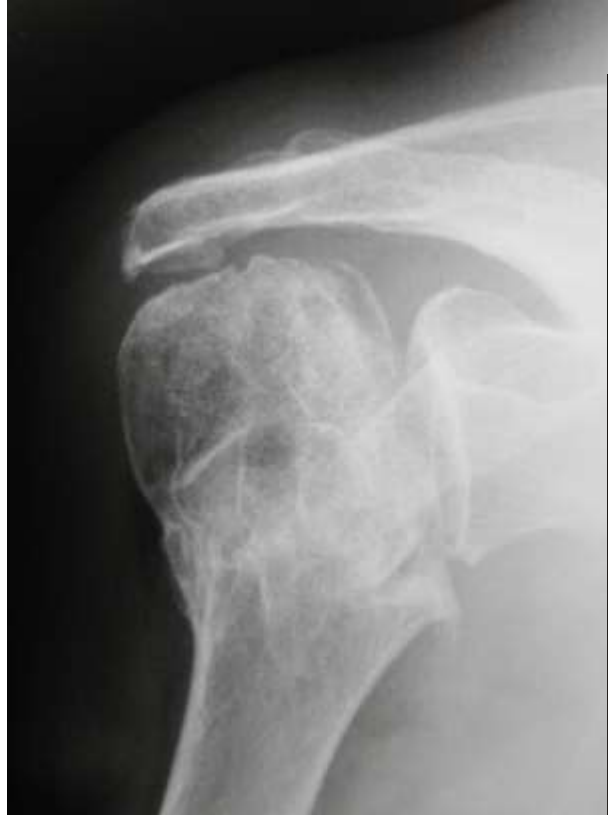
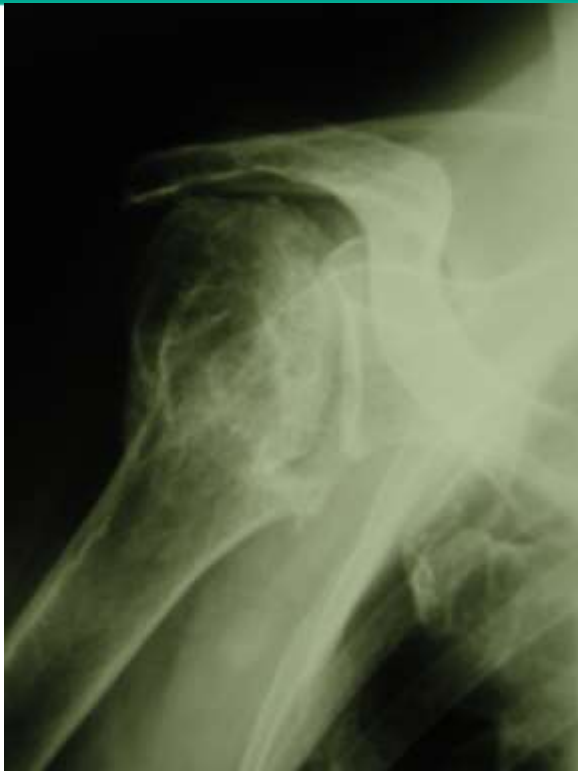3 part fract
Closed initial treatment
Impacted valgus
Malunion GT

osteotomy

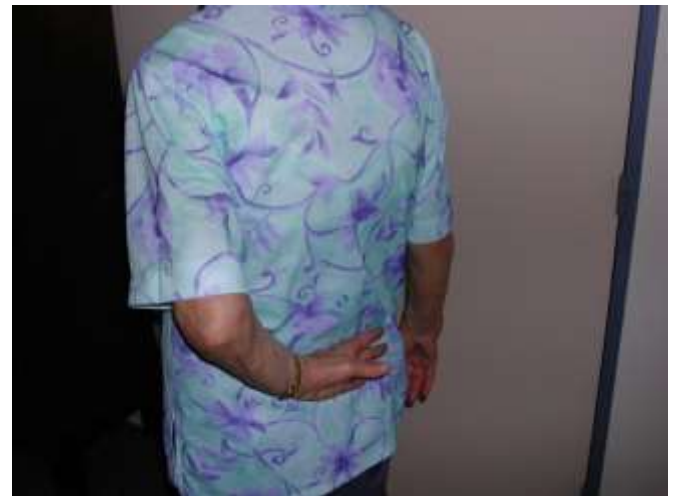
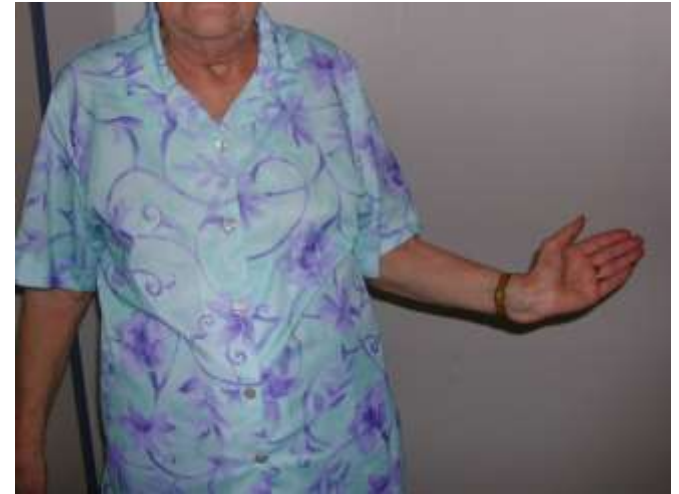
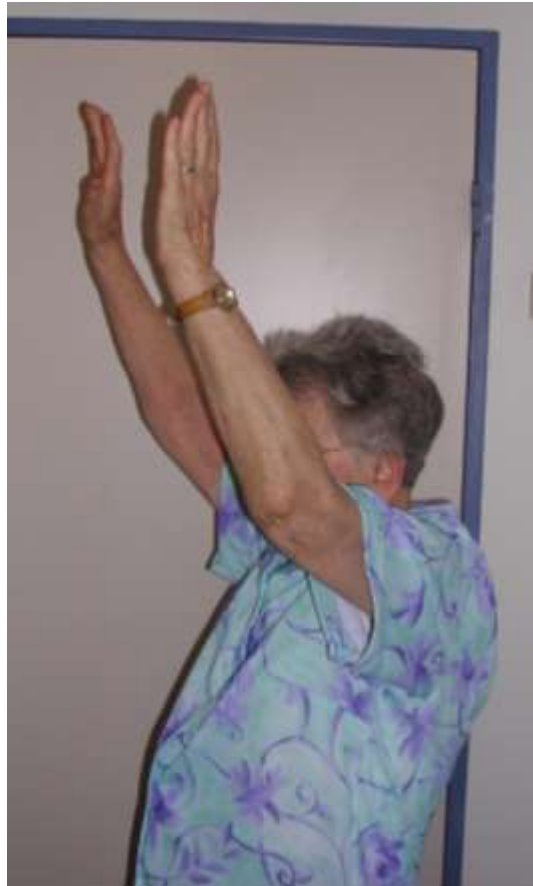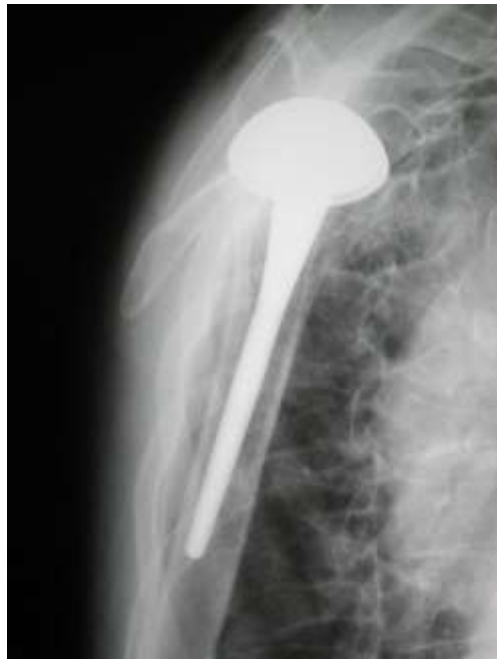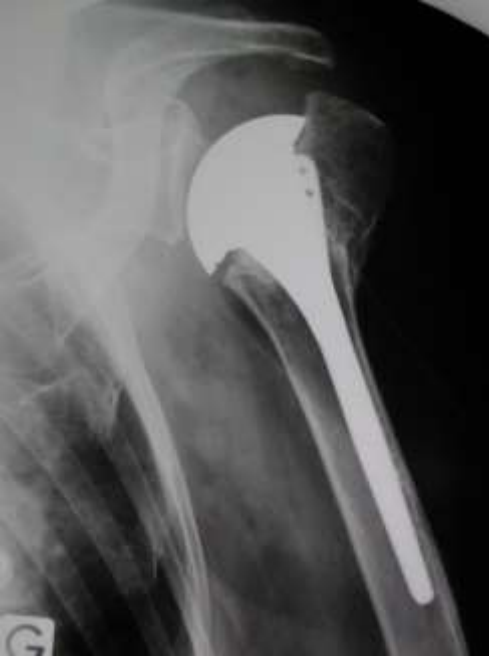Malunion GT necrosis HHead

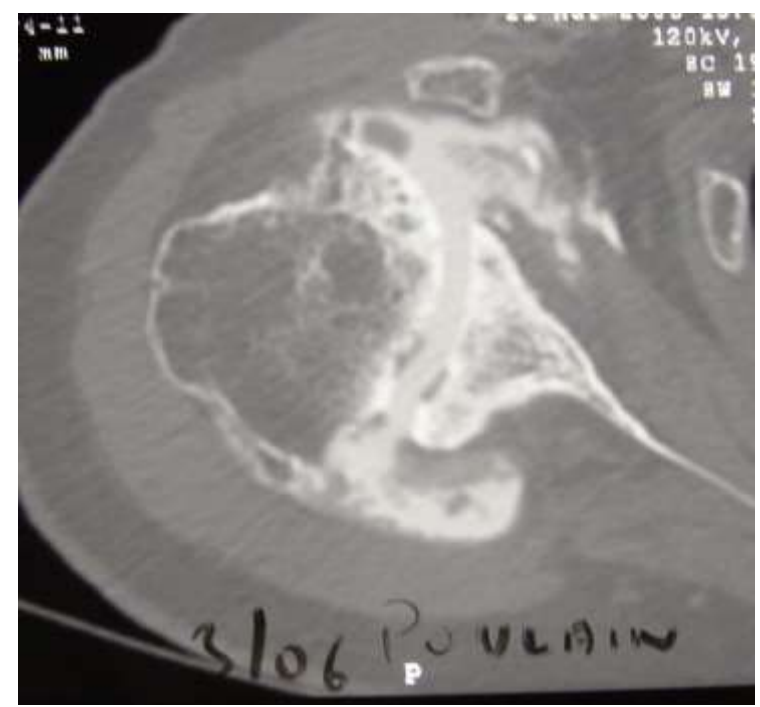
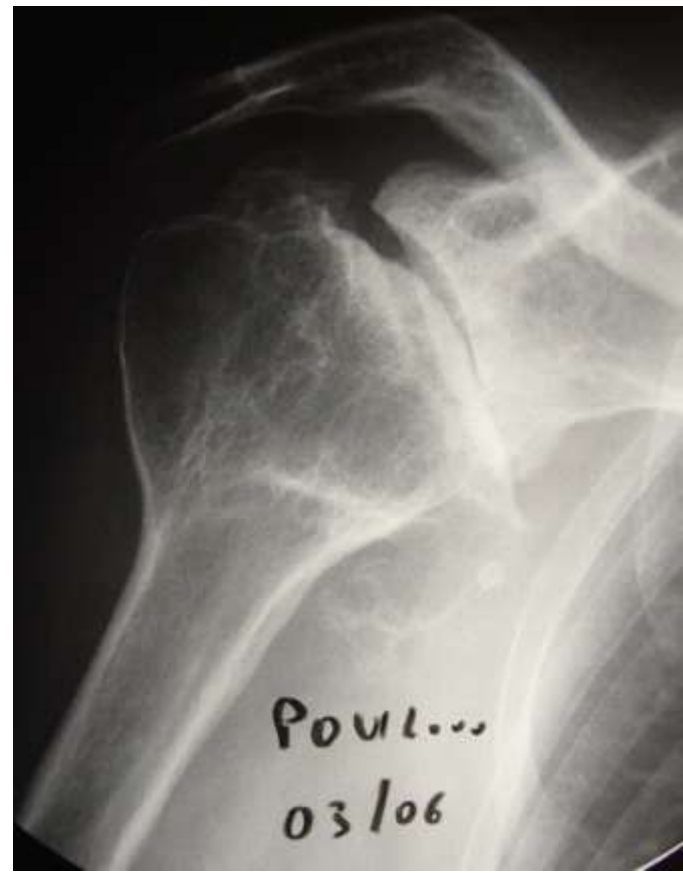
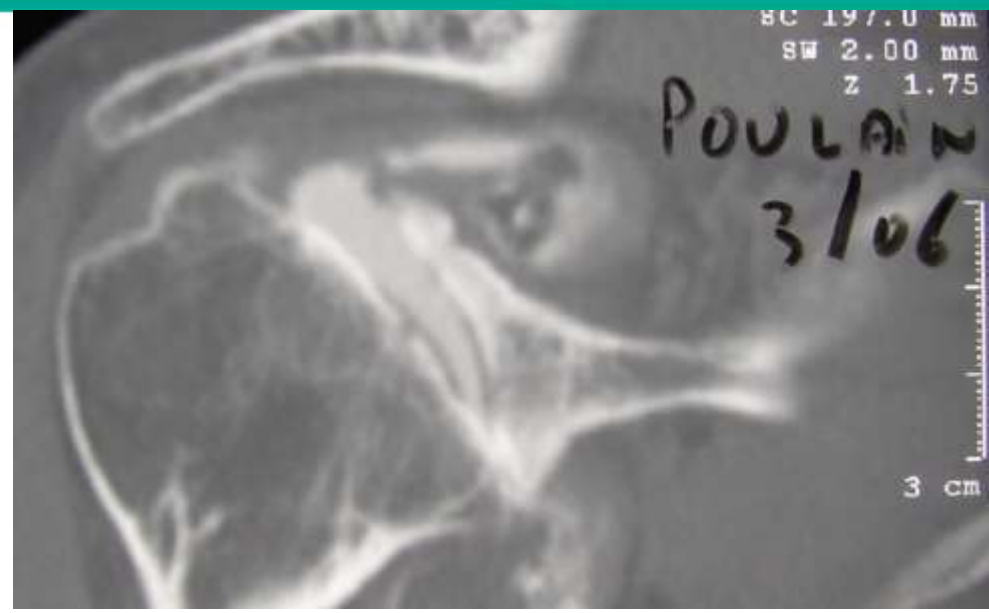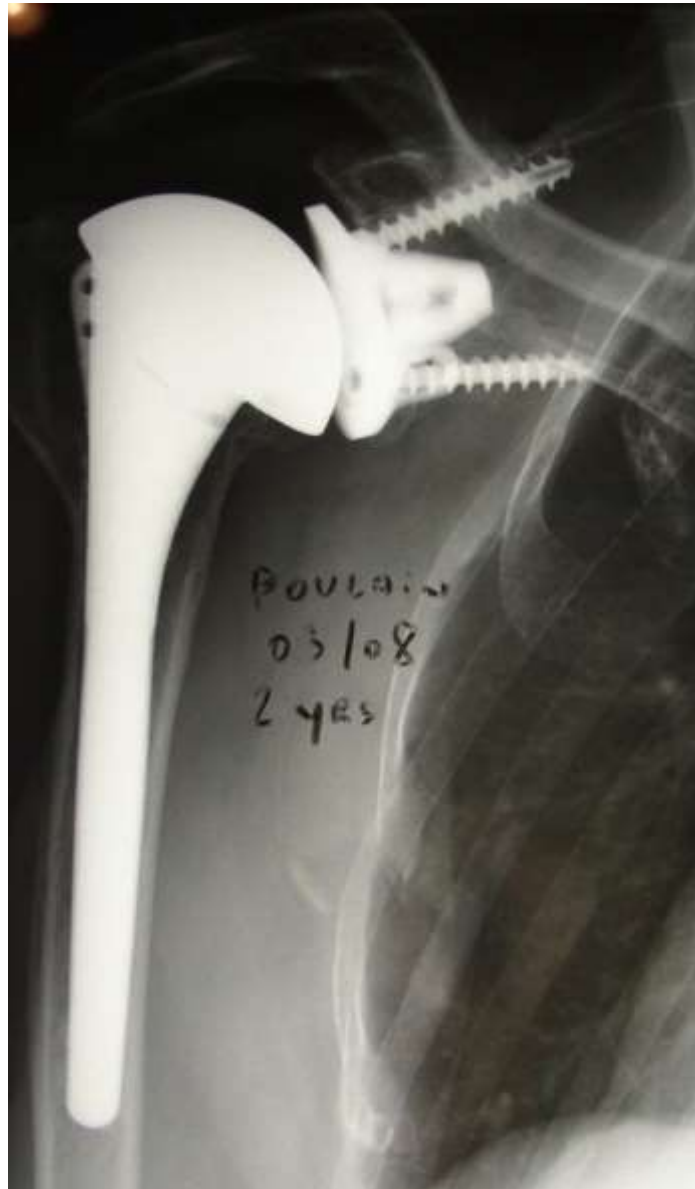4 fragments
Impacted valgus Fract
85 years old
Pain AAE 80° ER1 40°
Functionnal cuff
Constant score 27

Constant score 68
No pain



72 years old
4 part fract
Necrosis
Glenoid cartilage wear
Constant score 13





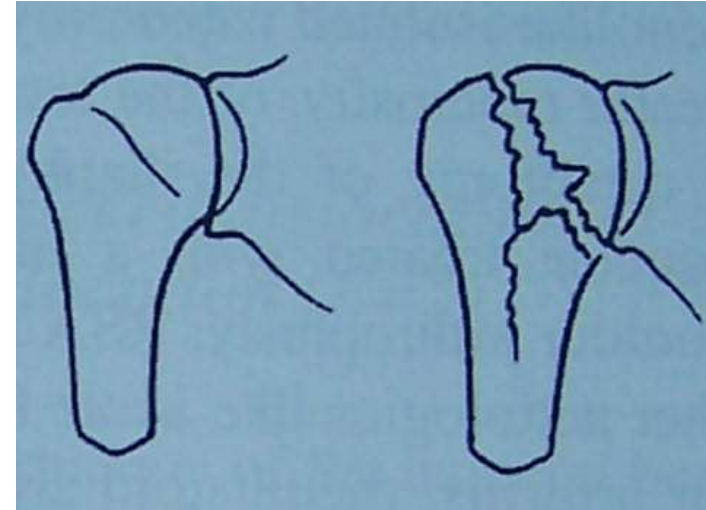
Type 2: chronic posterior dislocation (>6months)

Functionnal cuff

- Hemiarthroplasty
- >12months

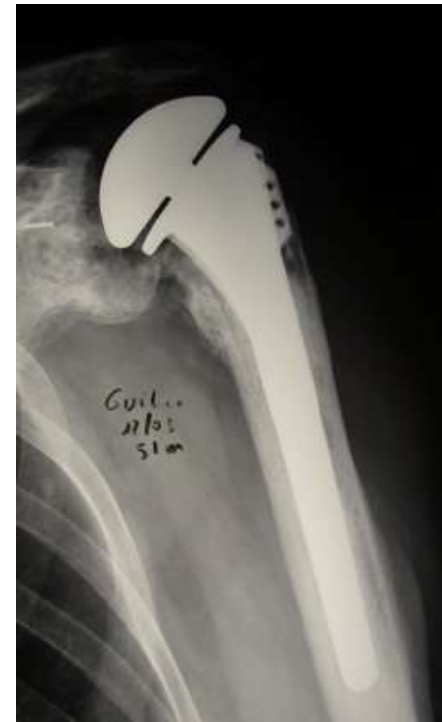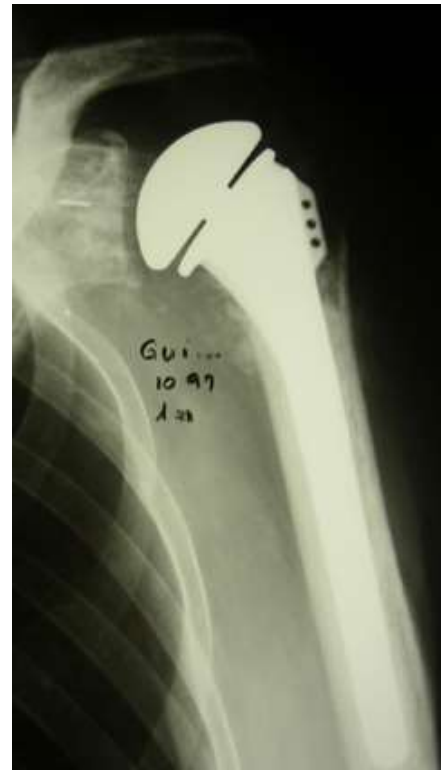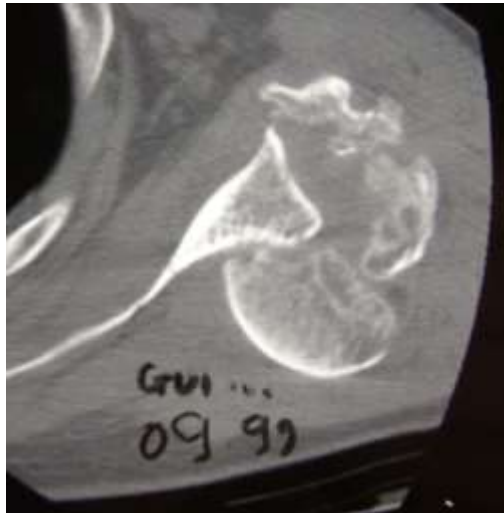Anatomic TSA (glenoid wear)

- Less retroversion

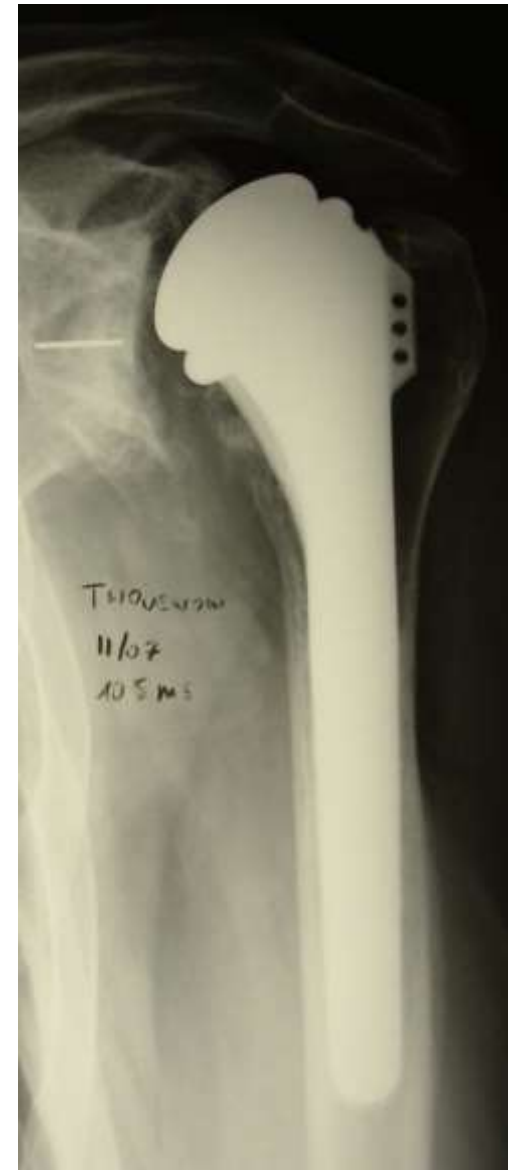
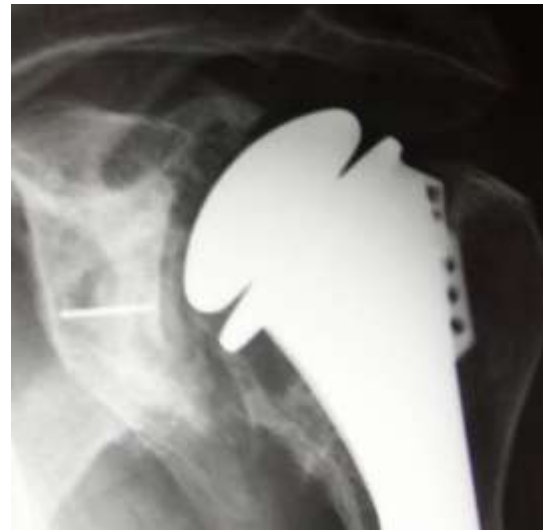
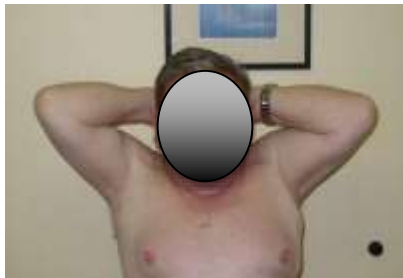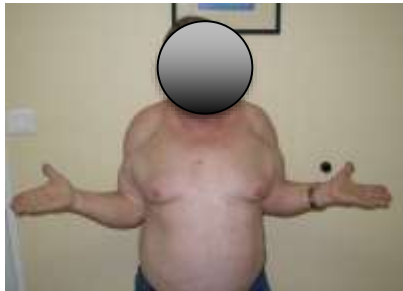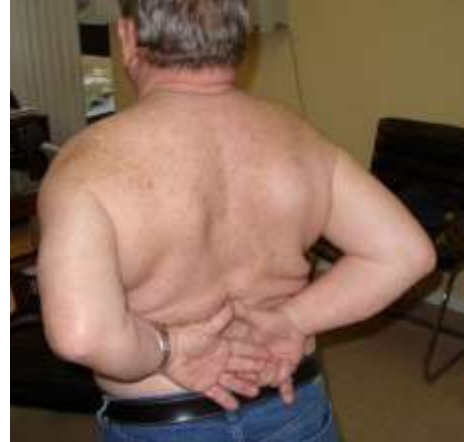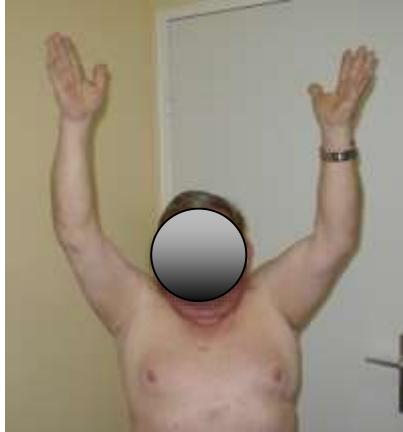Chronic post dislocation

- man 63 years old Cst 51mths=47(57%)



final flexion at 9 years = 170°
Cst=78 !!

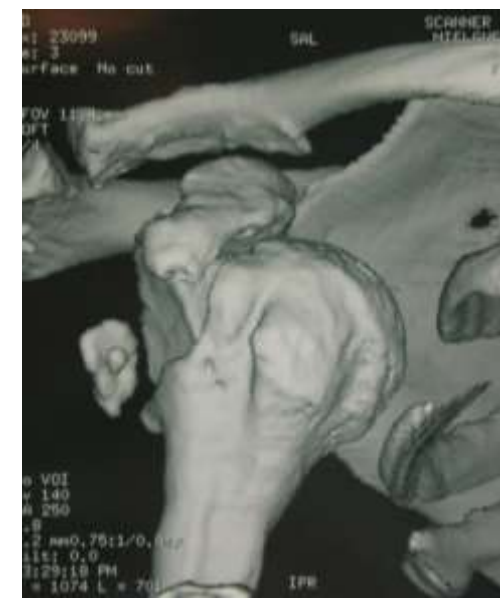
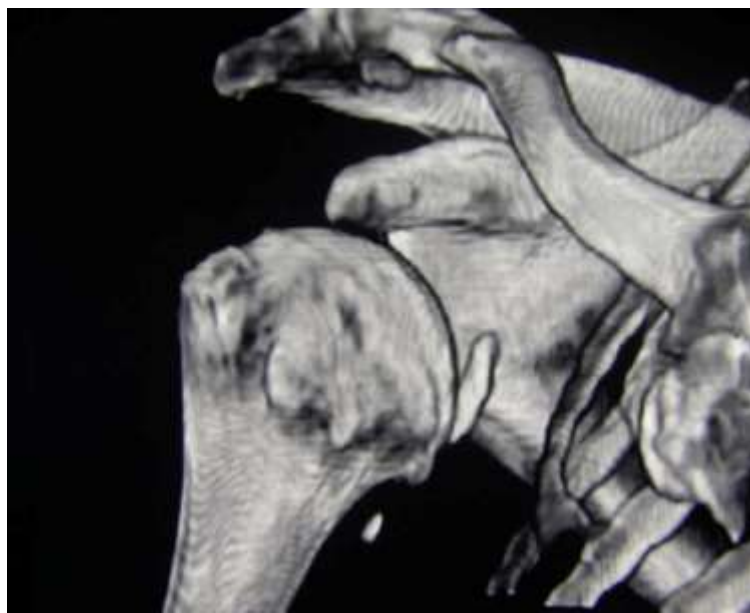
Type 2: chronic anterior dislocation (>6months) Fracture dislocation

No subscapularis

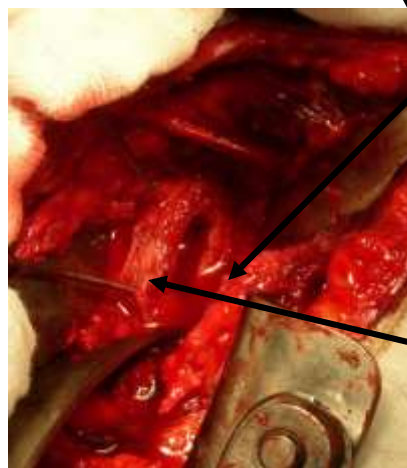
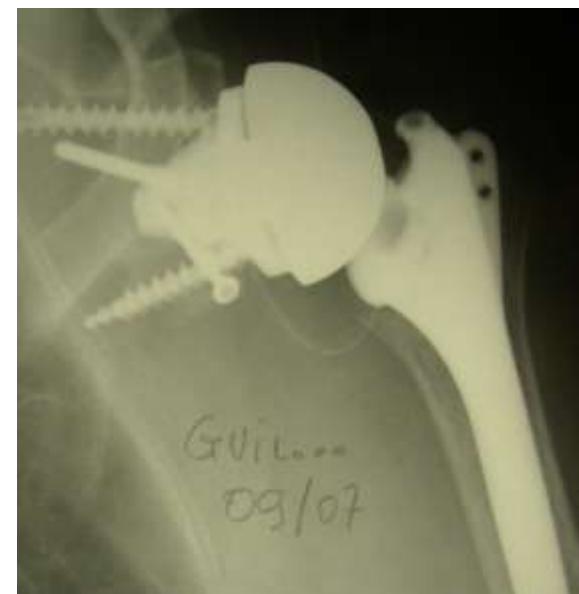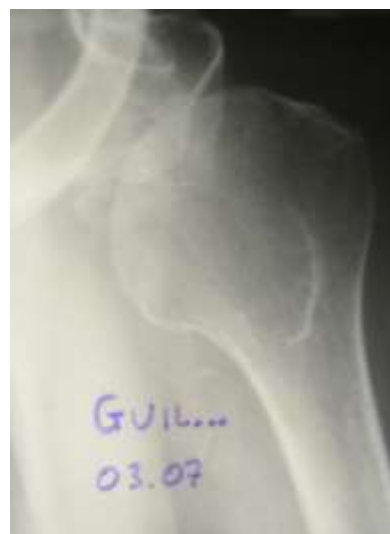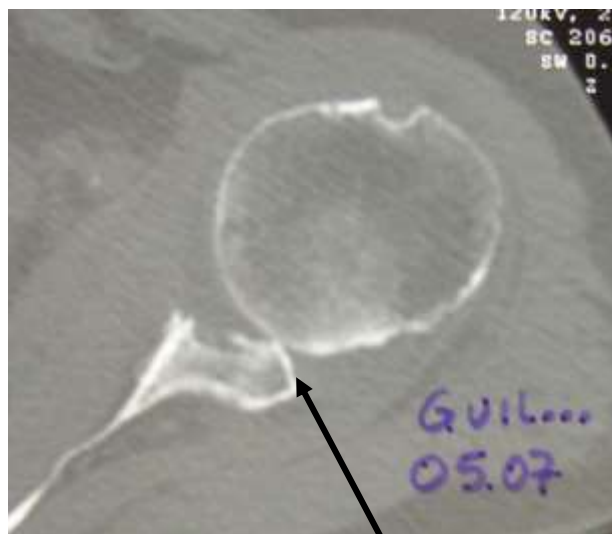
Reversed prosthesis

Contra indication Hemiarthroplasty



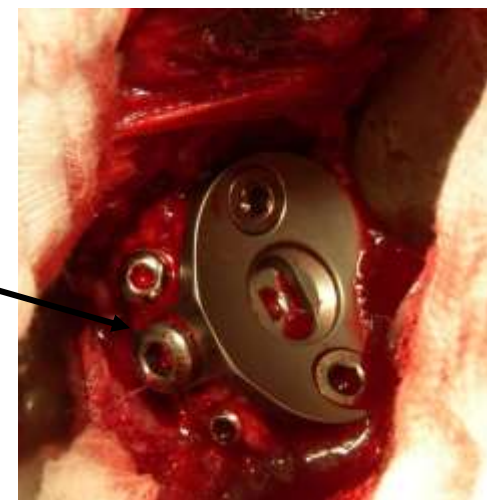
71 years old lady with a chronic ant dislocation

Postop X ray



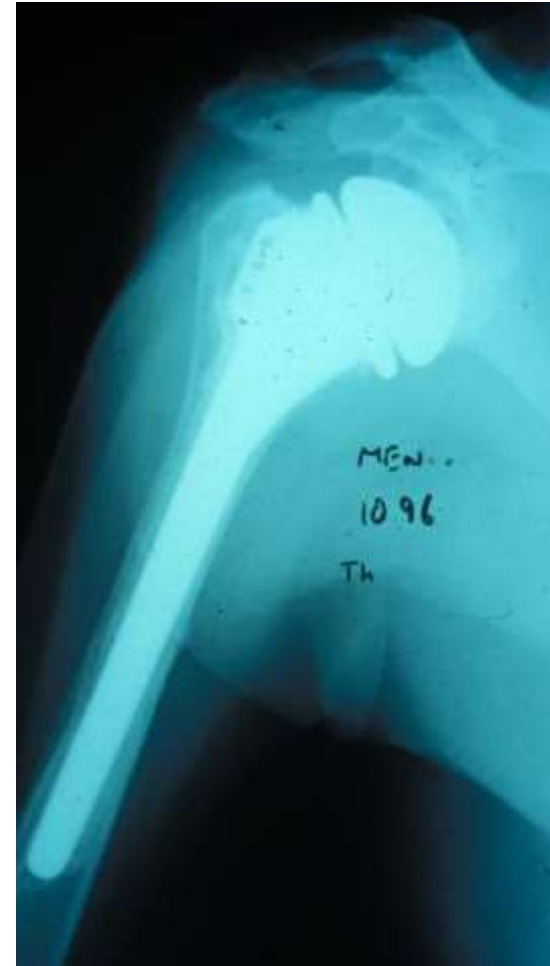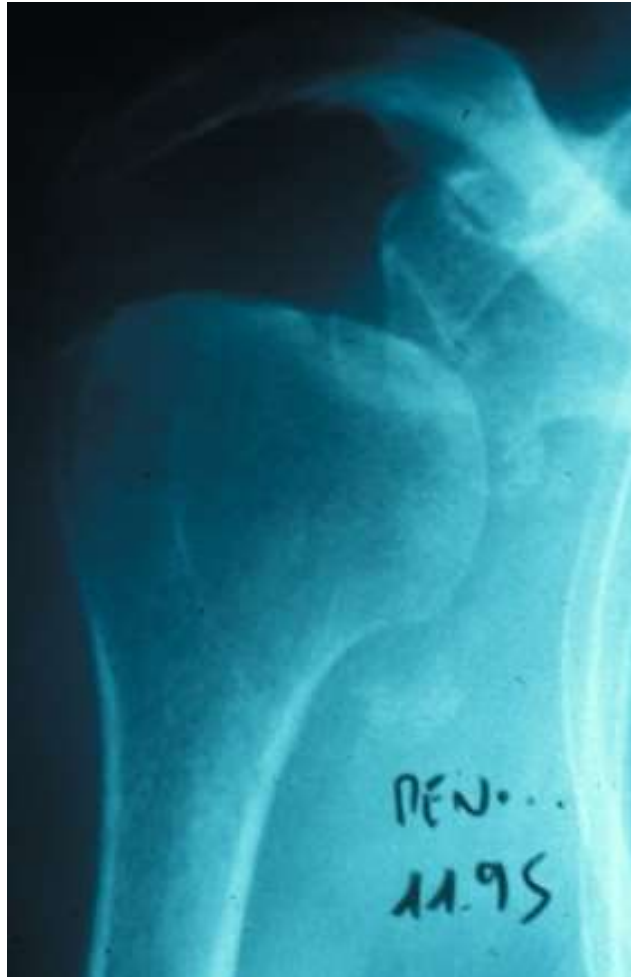**Intact Posterior edge of the glenoid
giving the good glenoid version
for the definite implant**

**Iliac crest graft in place
with temporary K wires**



Chronic anterior dislocation

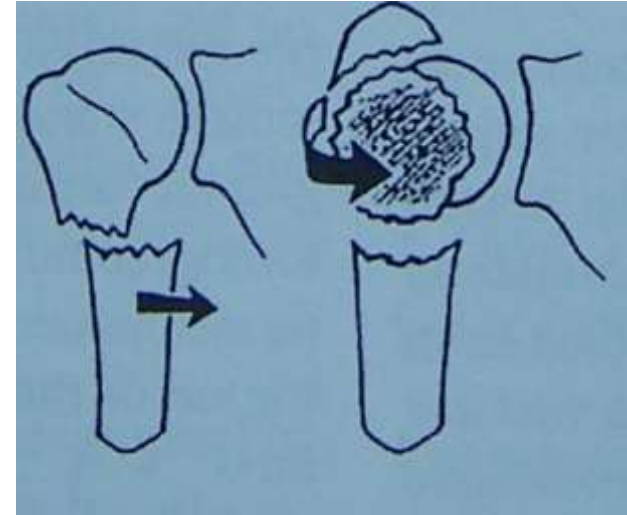
Hemiarthroplasty is not the good way !!!!



Type 3: surgical neck non union

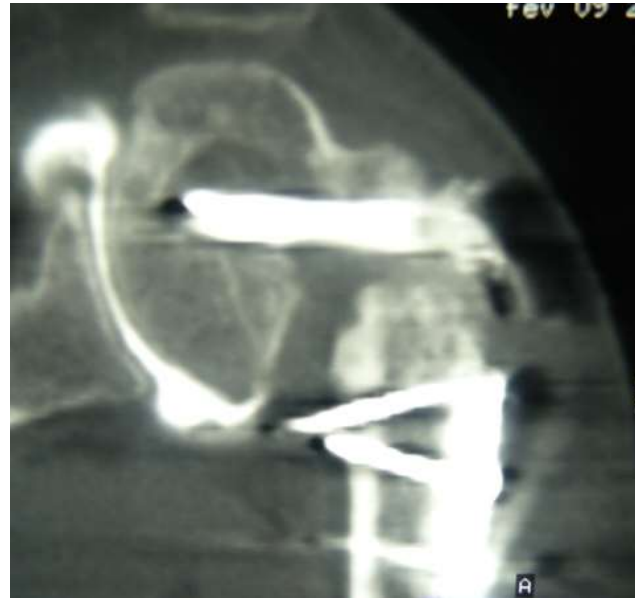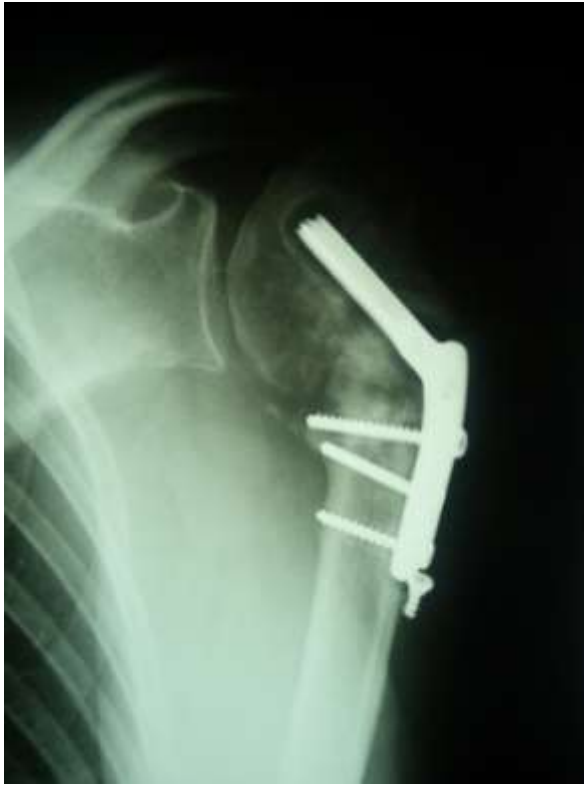Cuff is fonctionnal

Bone grafting (iliac crest)
+ plate Arthrolysis

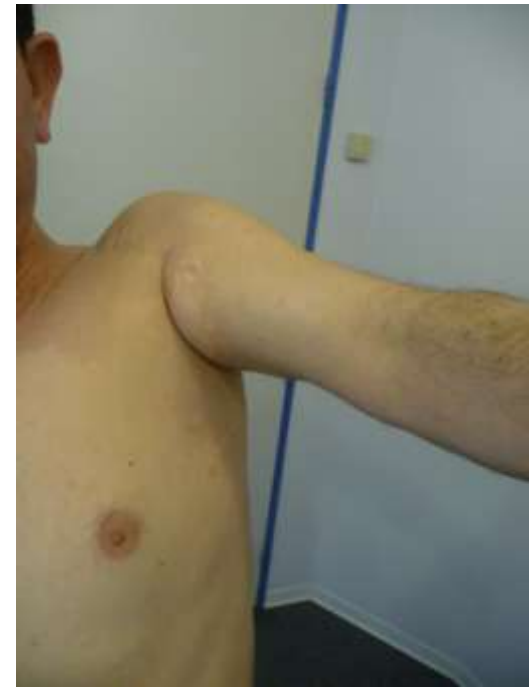


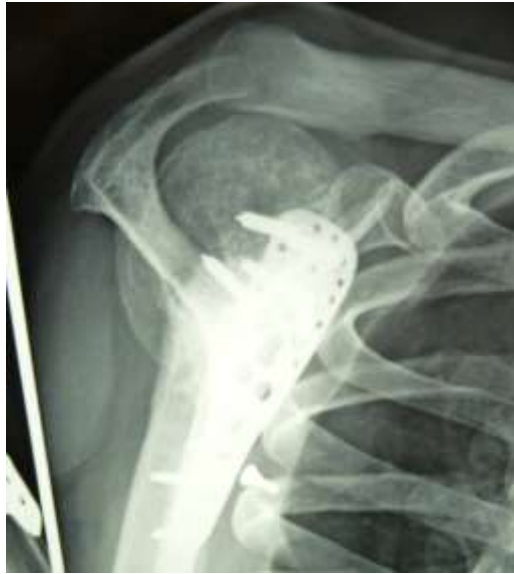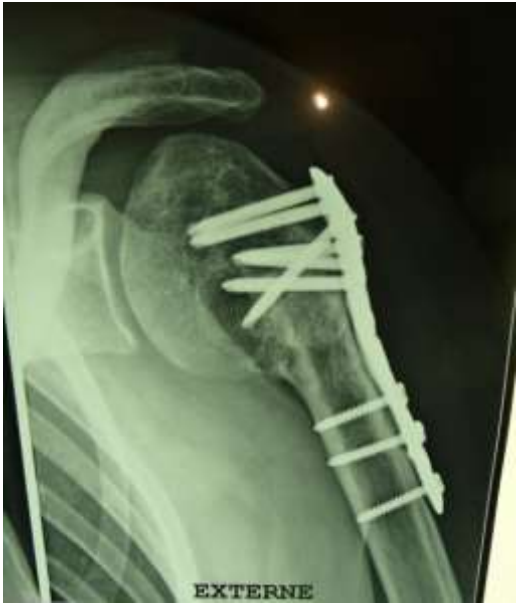*Cuff is no fonctionnal GT displaced
Stiff shoulder Cartilage wear
Osteoarthritis*

Reversed prosthesis



Non union
surgical neck



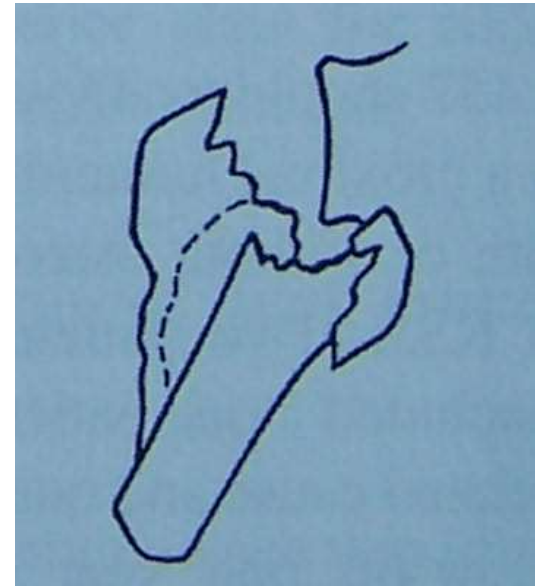

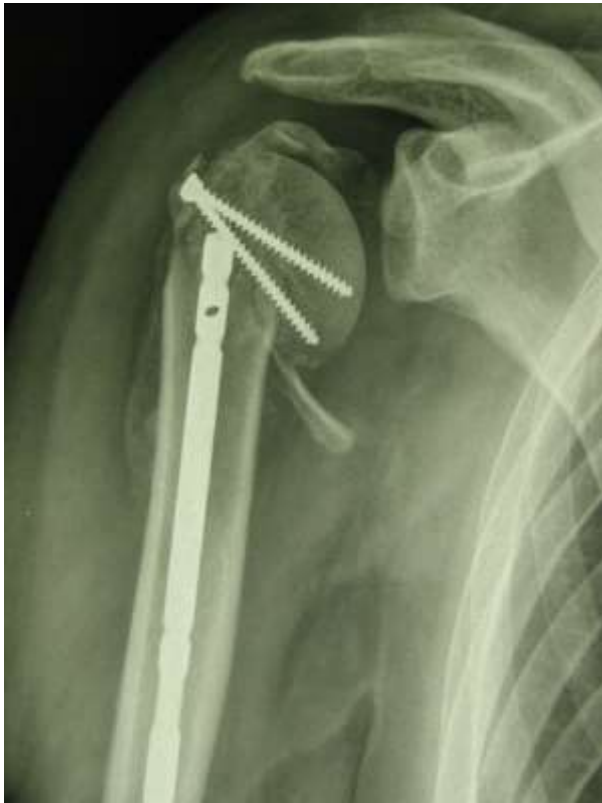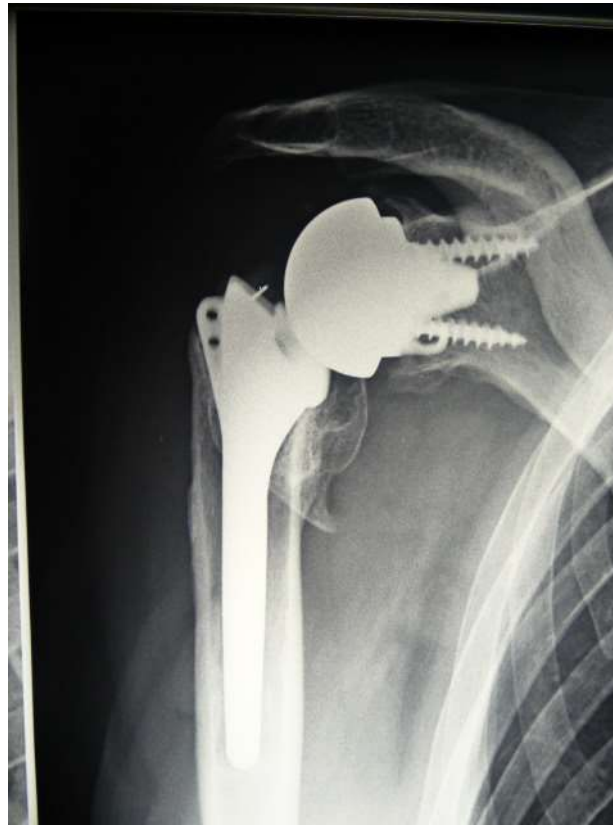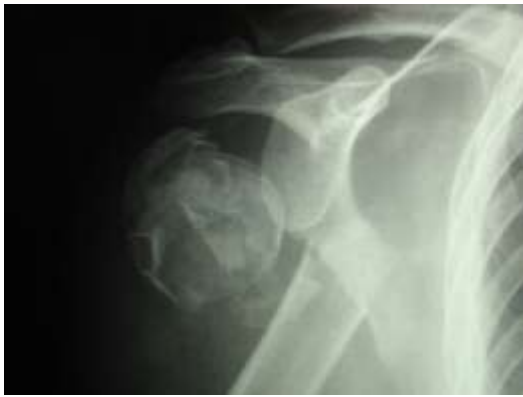Type 4: Fracture dislocation with non union GT

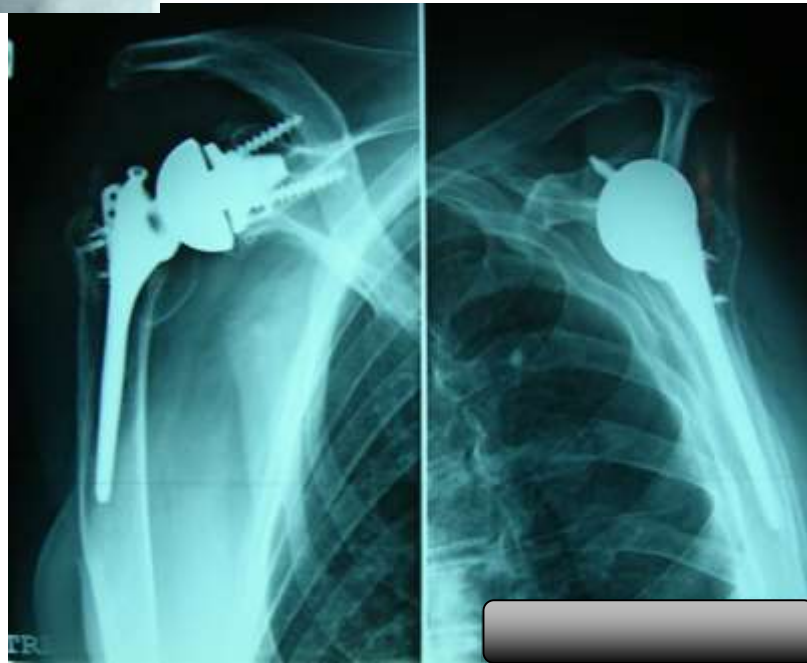
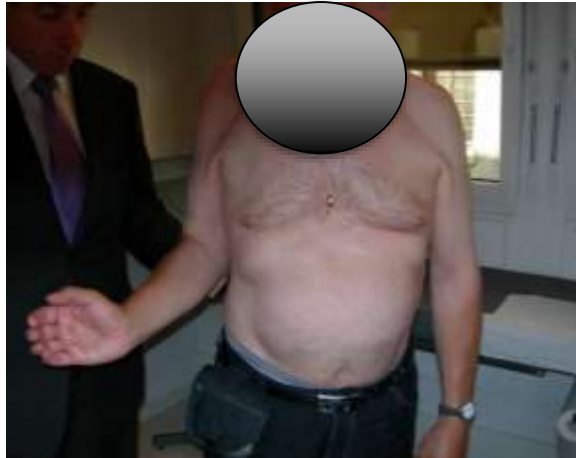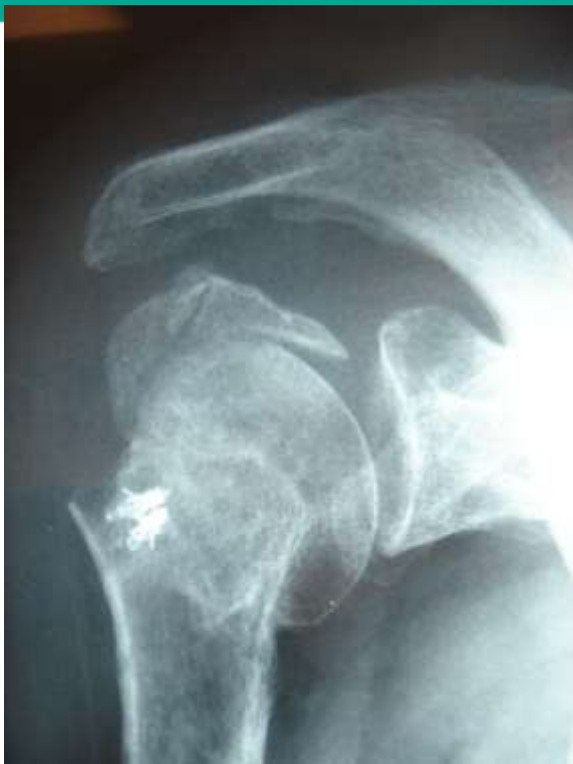No fonctionnal cuff

No continuity GT with diaphysis

- Reversed P
- Reversed + Episcopo
if lack of active ER



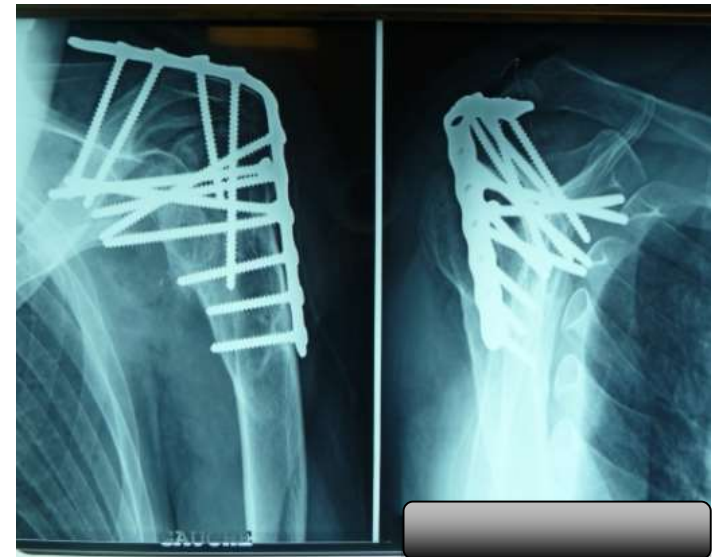



Shoulder arthrodesis

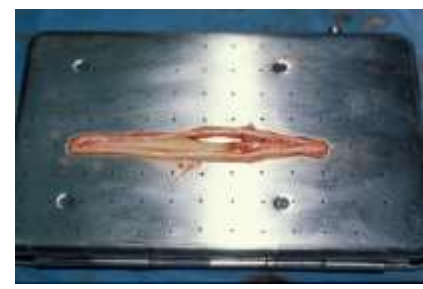
- Definitive paralysis of deltoid and cuff
(good serratus anterior)
- Chronic infection
- Young man (type 4)

Bone graft (iliac creast)
Fibular vascularized graft



Sequelea of proximal humeral fracture neurologic lesion

< 6 months



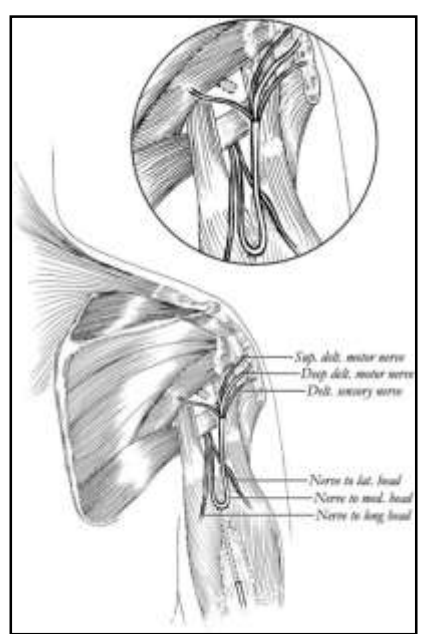
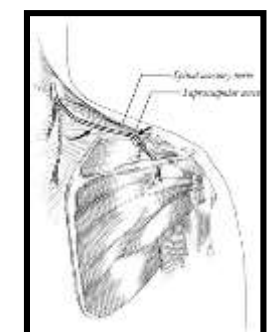
Nerve graft Axillary +/- Suprascapular N

12 -18months

Neurotisation

Radial triceps branch to axillary N

Spinal to suprascapular nerve



Take home messages

Great Tuberosity (GT) = cuff +++

FUNCTIONNAL CUFF

Osteotomy

Hemiarthroplasty (necrosis)

Anatomic total arthroplasty (Glenoid wear)

NO FUNCTIONNAL CUFF

Reversed prosthesis



PARIS
SHOULDER UNIT